

**PATIENT**

Rocket Valerio

**PRESENTING CLINICAL SIGNS**

consumed an unknown amt of onions

**SPECIES**

Canine

**BREED**

Poodle Mix

**SEX**

MN

**AGE**

3

**WEIGHT**

16.6

**INTERPRETED BY**R. McKenzie Daniel,  
DVM, DABVP  
(Canine and Feline)**IMAGING  
PERFORMED BY**

Jenn

**HOSPITAL NAME**Rockaway Animal  
Hospital**REFERRING VET**

Dr Maniar

**INVOICE  
24284****DATE**

03/25/2026

**ULTRASONOGRAPHIC EXAMINATION OF THE ABDOMEN****Urinary System**

The urinary bladder, trigone, cystourethral junction, and visible pelvic urethra exhibited normal thickness and tone. Anechoic urine was present in the lumen with no evidence of urine/lumen sediment, mineral, or calculi. The ureteral papillae were normal. The ureters were not visible which is normal. No evidence of inflammatory or neoplastic changes was noted.

Normal size and margination were present in the kidneys. A normal 1:3 cortex / medulla ratio and normal corticomedullary definition were maintained. The echogenicity of the cortex was similar to or slightly less than normal liver parenchyma while the medulla echogenicity was hypoechoic to the cortex with no evidence of pelvic dilation. The left kidney measured 3.5 cm in length. The right kidney measured 3.1 cm in length.

The area of the aortic trifurcation was free of pathology.

**Adrenal Glands**

The left adrenal gland was uniform in size and contour with a uniformly hypoechoic parenchyma. The left adrenal gland measured 0.43 cm width at the caudal pole. The right adrenal gland was uniform in size and contour with a uniformly hypoechoic parenchyma. The right adrenal gland measured 0.33 cm width at the caudal pole.

**Spleen**

The spleen exhibited a finely textured and homogenous parenchyma which was hyperechoic to the liver and renal cortical parenchyma. The capsule was smooth and regular without apparent expansion. The splenic vasculature at the hilus was normal in volume with no evidence of congestion or thrombosis. Acute to chronic inflammatory, neoplastic, or benign parenchyma changes were not noted.

**Liver/Gallbladder**

The liver was subjectively normal in size, structure, and contour. The liver parenchyma was uniform and hypoechoic to the spleen with a mild coarse echotexture. Normal vascular volume. The hepatic and portal vasculature were normal in appearance without signs of congestion. The gallbladder was non-distended in size with thin walls and primarily anechoic luminal content. The cystic and common bile ducts were normal.

**Gastrointestinal**

The stomach presented intact wall layering with a normal wall layer ratio. The lumen of the stomach contained mild non-shadowing ingesta sonographically suggestive of food echogenicity and lumen gas with no signs of obstruction or foreign material.

The small intestine presented intact wall layering with 1:3 muscularis/mucosa ratio. The lumen of the small intestine contained segmental mild, non-obstructive intestinal gas and non-shadowing ingesta to the level of the colon.



## PATIENT

Normal visible colon wall layers were present with apparent formed feces in lumen.

Rocket Valerio

## *Pancreas*

## SPECIES

The parenchyma of the left limb, body and right limb of the pancreas presented isoechoic to the adjacent omental fat. A normal curvilinear capsule contour of the pancreas was present. The visible pancreatic duct was normal. No signs of active inflammation or neoplastic disease was evident.

Canine

## *Free Abdomen*

## BREED

No omental masses, overt lymphadenopathy or peritoneal effusion was present.

Poodle Mix

## ULTRASONOGRAPHIC FINDINGS

### Primary

## SEX

- Normal gastrointestinal tract with mild gastrointestinal ingesta/gas

MN

## INTERPRETATION OF THE FINDINGS & FURTHER RECOMMENDATIONS

## AGE

The mild gastrointestinal ingesta is most suggestive of food echogenicity without evidence of foreign material or obstructive pattern. Potential for persistent dietary indiscretion within the gastrointestinal tract, i.e. onion is not definitively excluded. Gastrointestinal support included gastroprotectants and detoxification with close monitoring for evidence of hemolysis, anemia or progressive gastrointestinal signs is recommended.

3

## WEIGHT

16.6

## INTERPRETED BY

R. McKenzie Daniel,  
DVM, DABVP  
(Canine and Feline)

## IMAGING PERFORMED BY

Jenn

## HOSPITAL NAME

Rockaway Animal  
Hospital

## REFERRING VET

Dr Maniar

## INVOICE

24284

## DATE

03/25/2026



**PATIENT**

Rocket Valerio

**SPECIES**

Canine

**BREED**

Poodle Mix

**SEX**

MN

**AGE**

3

**WEIGHT**

16.6

**INTERPRETED BY**

R. McKenzie Daniel,  
DVM, DABVP  
(Canine and Feline)

**IMAGING PERFORMED BY**

Jenn

**HOSPITAL NAME**

Rockaway Animal  
Hospital

**REFERRING VET**

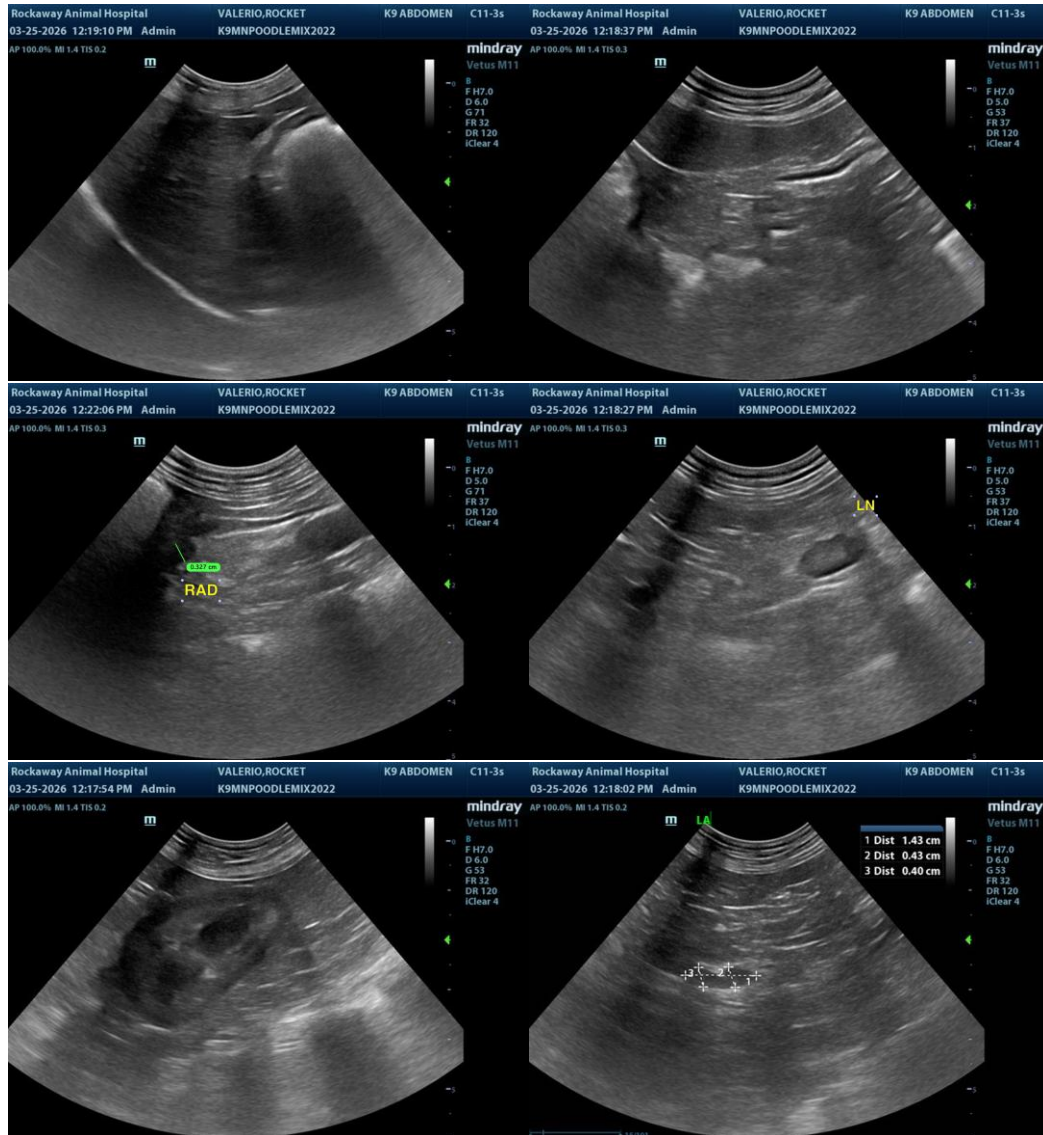
Dr Maniar

**INVOICE**

24284

**DATE**

03/25/2026



The information and recommendations provided are based on the images presented by the referring veterinarian/sonographer. No evaluation can be communicated regarding pathology that was not visible in the image/video clips provided.

Thank you for this referral. If the clinical or image interpretation does not parallel your findings or if I can be of any further assistance, please contact me.

R. McKenzie Daniel, DVM, DABVP (Canine/Feline Practice)  
[info@sonopath.com](mailto:info@sonopath.com)